The Distal Extension Case: An Alternative Restorative Design for Implant Prosthetics

*Neil L. Starr, DDS**

A restorative design is introduced in preference to the implant-supported bar, clip, or ball-type removable prosthesis. It has been necessary to develop an alternative treatment approach to the placement and restoration of implants in the posterior mandible or maxilla. In an examination of the available therapeutic choices and their rationales, this treatment option offers greater function, esthetics, and comfort. Four maxillary and one mandibular arches were reconstructed with anterior implant-supported fixed bridges/splinted restorations and a precision partial denture design posteriorly, using an extracoronal universal ball attachment. These cases have demonstrated minimal maintenance up to 7 years in function. (Int J Periodontics Restorative Dent 2001;21:61–67.)

*Adjunct Clinical Assistant Professor, Department of Periodontics, University of Pennsylvania, School of Dental Medicine, Philadelphia; and Private Practice in Prosthodontics, Washington, DC.

Reprint requests: Dr Neil L. Starr, Dupont Medical Building, 1234 19th Street NW, Suite 306, Washington, DC 20036. e-mail: starrteeth@aol.com

The distal extension problem presents itself when one or more posterior segments of maxillary or mandibular teeth are entirely missing. In the past, this has required replacement with a tooth-tissue–supported removable prosthesis. The basic requirements of the removable partial denture are *(1)* to aid in masticatory function; *(2)* to brace the abutment teeth; *(3)* to be retentive and resistant to displacement; *(4)* to be easily inserted and removed; *(5)* to satisfy any phonetic limitations; *(6)* to be esthetic; and *(7)* to be comfortable.

Successful function with the posterior removable appliance depends on the design of the centric holding areas of the remaining anterior teeth and their ability to effect anterior guidance. Simultaneous contact should occur on the fixed abutments as close to the desired occlusal vertical dimension as possible. Lateral and protrusive movements should also be primarily on the fixed abutments.[1] Generally, this can be achieved where posterior teeth have been lost by caries, traumatic insult, or

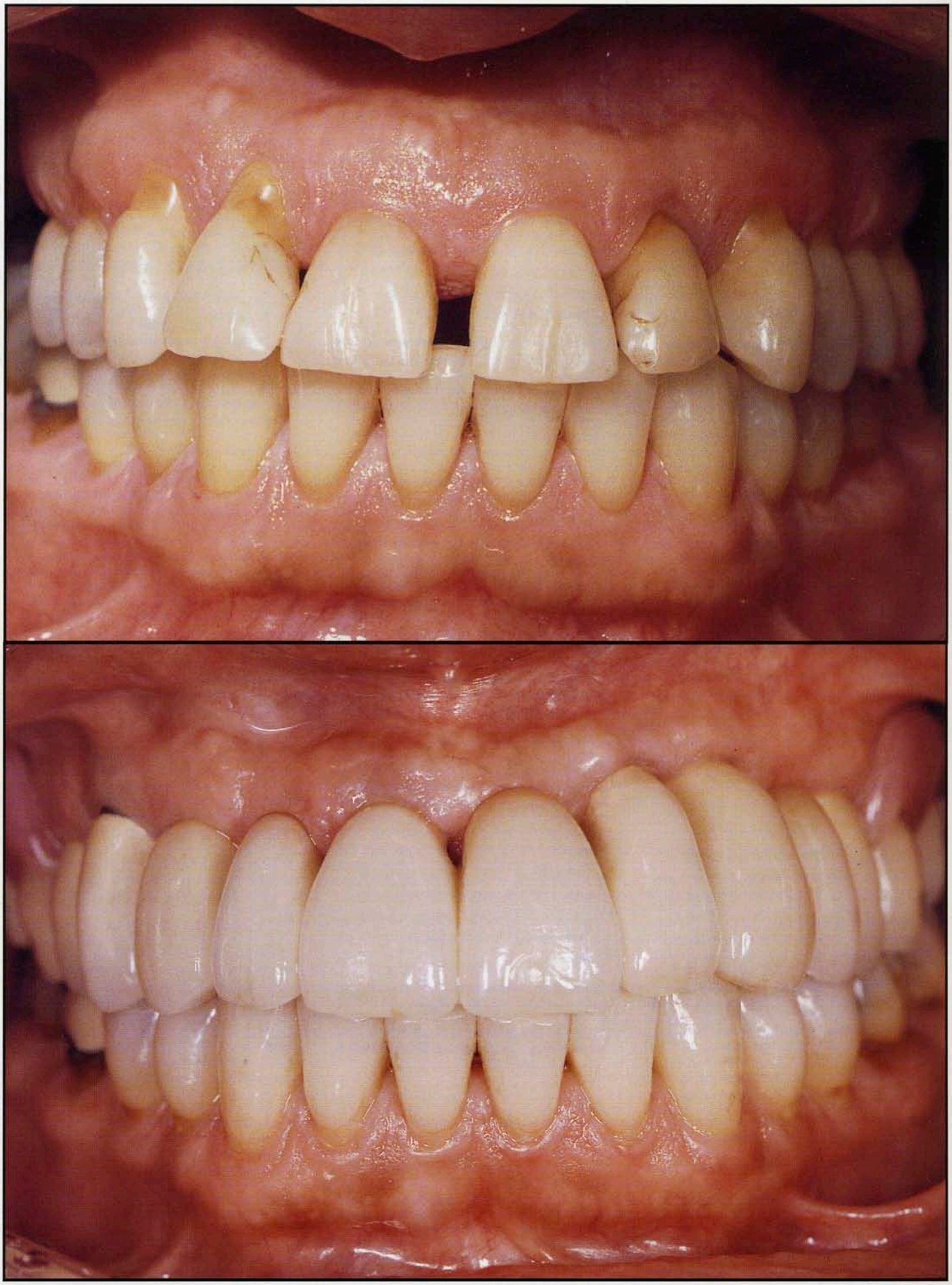

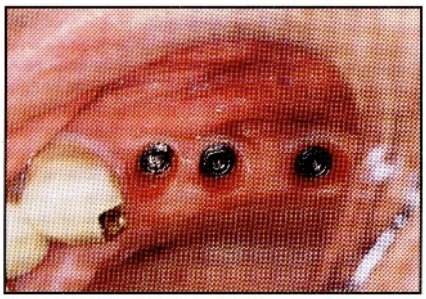

Fig 1a (left) *Endosseous implants are placed at the sites of the maxillary left first and second premolars and first molar after sinus augmentation.*

Fig 1b (right) *Fixed-splinted ceramogold crowns for implant sites at the maxillary left first and second premolars and first molar in concert with anterior fixed-splinted ceramogold crownwork (Fig 2).*

iatrogenics, ie, the periodontally resistant patient.

Normally, the occlusal vertical dimension is supported by the posterior occlusion. With posterior tooth loss, the forces of occlusion must be received by the remaining anterior teeth, which are not well designed for this function. Additionally, these remaining anterior teeth must provide anterior guidance, disarticulating the posterior teeth through excursive movements of the mandible, so periodontal compromise can have a significant impact on their long-term function and viability.

Before the advent of endosseous implantology, one approach to the distal extension problem that demonstrated limited success was the periodontal prosthesis with cantilevered pontics in the positions of missing maxillary second premolars.[1–4] Unfortunately, cement washout with ensuing caries or fracture of distal abutments compromised the longevity of these restorations. Another, more successful approach is the use of a precision partial denture design posteriorly with a fixed anterior bridge or splint.[1,5] Clinicians have subscribed to the use of intracoronal precision attachments like the Stern GL attachment (male-female dovetail latch design) in the distal surfaces of the distal abutments of the remaining anterior teeth or premolars to effectively retain the tooth-tissue–supported prosthesis under functional loads and at rest.

Some clinicians have advocated "stress-breaking" attachments for the more periodontally compromised situations or for nonsplinted anterior teeth/crowns, but experience has demonstrated that these attachments may create more stress over time, causing more torque to abutment teeth and the acceleration of ridge resorption.[1,2] One must not lose sight of the fact that the purpose of the appliance is to serve as a chewing platform for masticatory efficiency, to satisfy esthetic and phonetic needs, and to enhance and support the buccal musculature. Unlike a tooth-supported posterior occlusion, it does not support the occlusal vertical dimension and facial height by itself.[1]

When the patient is periodontally susceptible and both posterior segments in the same arch are seriously compromised or missing, the remaining anterior teeth may be stressed unfavorably. Placing posterior implants with fixed/splinted crown and bridgework is the treatment of choice for this patient type.[7] Depending on the individual strength of the remaining anterior teeth, it may or may not be advisable to splint the anterior segment[2] (Figs 1 and 2).

Frequently, there is a lack of alveolar bone height and/or width superior to the maxillary antrum. Sinus bone augmentation[8–10] or onlay grafting[11] must first be performed to create an adequate quantity and quality of bone for successful osseointegration. Then, unilateral or bilateral implant-supported crowns, either individual or splinted, would allow restoration of the edentulous ridges with foundationally stable crownwork that will truly provide posterior occlusal function (Fig 1).

With progressive tooth loss, there is a disparity between the residual alveolar bone height posteriorly versus anteriorly.[8–11] This is often because of the extent and severity of periodontitis posteriorly and anteriorly; the timing of tooth

loss posteriorly versus anteriorly; and the degree of ridge resorption in each region, influenced by the removable denture base in function. As a consequence, there is often more bone available to consider implant restoration in the premaxillary region than there is posteriorly. A common scenario is one in which the posterior teeth are missing or hopelessly compromised with minimal alveolar bone and the compromised anterior teeth are no longer able to support normal function. Clearly, posterior sinus bone augmentation[8–10] or onlay grafting,[11] posterior endosseous implant placement, anterior tooth removal (some or all), and anterior implant placement followed by fabrication of fixed anterior and posterior implant-supported restorations would be the treatment plan of choice (Fig 3).

Situations at a clinical level have necessitated the development of an alternative treatment approach to the placement and restoration of implants in the posterior maxilla and/or posterior mandible. Examples of such situations are those patients who have sinus complications that would preclude successful osseointegration; patients who strongly fear any antral manipulation or inferior alveolar nerve repositioning; patients with systemic considerations that may influence the sinus bone maturation; and previous tissue insult that compromised blood supply and influenced cellular viability, eg, radiation therapy, chemotherapy, infection, or trauma. Other categories are the patient who has time and cost constraints or the

Anterior teeth that are able to withstand normal functional forces:
- Posterior fixed implant-supported restoration only
- Anterior fixed-splinted teeth and posterior fixed implant-supported restoration
- Attachment placement in crowns of the distal-most anterior teeth with precision removable partial denture posteriorly
- Anterior fixed-splinted teeth with precision attachments at distal abutments and precision partial denture posteriorly

Very weak anterior teeth that are unable to withstand normal functional forces:
- *Surgical: (1)* anterior tooth removal (some or all); *(2)* anterior endosseous implant placement; *(3)* posterior endosseous implant placement
  Restorative: fabrication of fixed-splinted or bridged implant-supported anterior and posterior restorations
- ***Surgical: (1)* anterior tooth removal (some or all); *(2)* anterior endosseous implant placement**
  ***Restorative:* fabrication of anterior fixed implant-supported splint or partial denture with attachments at distal-most abutments to retain a posterior precision removable partial denture**
- *Surgical: (1)* anterior tooth removal (some or all); *(2)* anterior endosseous implant placement
  Restorative: fabrication of anterior splinted implant-supported bar with clip or ball attachment overdenture or spark-erosion removable prosthesis
- *Surgical:* anterior tooth removal (some or all)
  Restorative: fabrication of complete overdenture/denture

Fig 2 *Restorative treatment planning for the maxillary arch with* **missing or hopeless posterior teeth and available alveolus.**

Anterior teeth that are able to withstand normal functional forces:
- Anterior fixed-splinted teeth with posterior sinus bone augmentation and/or posterior onlay grafting; posterior endosseous implant placement with posterior fixed implant-supported restoration
- Anterior fixed-splinted teeth with clasp partial denture or precision partial denture posteriorly
- Attachment placement in crowns of distal-most abutment teeth with precision removable partial denture posteriorly
- Clasp removable partial denture only

Very weak anterior teeth that are unable to withstand normal functional forces:
- *Surgical: (1)* anterior tooth removal (some or all); *(2)* anterior endosseous implant placement; *(3)* posterior sinus bone augmentation/only grafting; *(4)* posterior endosseous implant placement
  Restorative: fabrication of fixed-splinted anterior and posterior restorations
- ***Surgical: (1)* anterior tooth removal (some or all); *(2)* anterior endosseous implant placement**
  ***Restorative:* fabrication of anterior fixed implant-supported splint or partial denture with attachments at distal-most abutments to retain a posterior precision removable partial denture**
- *Surgical: (1)* anterior tooth removal (some or all); *(2)* anterior endosseous implant placement
  Restorative: fabrication of anterior splinted implant-supported bar with clip or ball attachment overdenture or spark-erosion removable prosthesis
- *Surgical:* anterior tooth removal (some or all)
  Restorative: fabrication of complete overdenture/denture

Fig 3 *Restorative treatment planning for the maxillary arch with* **missing or hopeless posterior teeth and lack of available alveolus.**

patient who has successfully worn a removable prosthesis and who is comfortable with this design.

With these limitations precluding the placement of implants posteriorly and as the dentition is more and more compromised by periodontitis, tooth loss, and ridge resorption, the tendency is to restore the dental arch via the most universal treatment approach. However, with the increasing demand for esthetics as well as function, current treatment options must be reevaluated, especially when constructing restorations for the maxillary arch.

With significant horizontal and vertical residual ridge loss anteriorly and minimal alveolus above the maxillary sinuses, and when bone and soft tissue deficiencies cannot be compensated for, the generally accepted treatment plan might involve endosseous implant placement into available premaxillary sites, followed by fabrication of a splinted bar and removable clip-on or attachment overdenture[12,13] or spark-erosion removable prosthesis (Figs 3 and 4). This overdenture prosthesis is designed as a combined implant-retained and tissue-supported restoration.

For those situations in which the anterior alveolus has experienced minimal to moderate vertical and horizontal ridge loss[14] in the range of 3 to 7 mm with minimal remaining alveolar height posteriorly, a restorative treatment plan is proposed as an alternative to the splinted bar and clip/attachment overdenture design. The approach involves an anterior fixed implant-supported bridge or splint with a precision partial denture posteriorly (Fig 3). This design allows for a rigidly fixed implant restoration and a separate tissue-supported restoration.

Rationale and case presentation

The fixed anterior and removable posterior prosthetic design has many advantages. It eliminates any esthetic and vanity issues associated with removing one's front teeth to clean the prosthesis. There is minimal wear and tear on parts compared with the regular and frequent removal of bar-, clip-, or ball-design removable prostheses. The fixed implant-supported anterior bridge/splint allows the clinician to establish normal anterior esthetics, develop normal emergence profiles of crowns relative to the profiles of natural teeth, and establish normal phonetics via crown and bridge form. One can restore and maintain the occlusal vertical dimension with a canine-to-canine or premolar-to-premolar occlusion of the fixed anterior ceramogold implant or implant- and tooth-supported bridge or splint and develop normal anterior guidance features.

Four patients presented with maxillary arches severely compromised by periodontitis. The maxillary sinuses precluded the placement of endosseous implants distal to the premolar region unless antral bone augmentation was performed. The patients refused bone augmentation and accepted the author's approach to treatment, which involved creating an implant-supported anterior fixed-splinted restoration with a precision partial denture posteriorly.

In one of these cases, a 38-year-old woman was diagnosed with severe periodontitis that had ravaged virtually all maxillary teeth (Fig 5). As an interim measure, a number of these teeth were used strategically to support a fixed provisional restoration. Endosseous implants were subsequently placed throughout the premaxilla and as far distal as the maxillary sinuses would allow (Fig 6). After a period of osseointegration/maturation, a fixed bridge/splint was fabricated for the anterior group, with extracoronal precision attachments (ASC-52, Attachments and Implants International)[15] built at the distal surfaces of the distal-most crown abutments; a precision partial denture was fashioned to replace the missing posterior teeth.[16–18]

The provisional restoration protected the remaining prepared teeth and maintained the occlusal relations. The transitional implant-supported or assisted restoration, which followed implant uncovering, allowed the exchange of weak tooth support for strong anterior implant support and maintenance of occlusal function, essentially serving as a blueprint of the final restoration to come.

Implant-level impressions were then taken of all endosseous implants and any prepared abutment teeth, and a master model was fabricated. Occlusal registrations provided careful articulation of maxillary and mandibular casts for fabrication

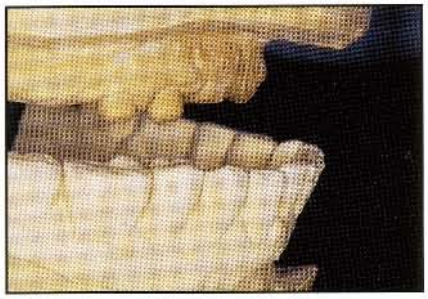

Fig 4a *Marked anteroposterior disparity: the maxillary arch is very recessed relative to the mandible. This differential allows one to appreciate the importance of prosthetically restoring not just teeth but gingiva and alveolar processes via the removable bar-retained overdenture.*

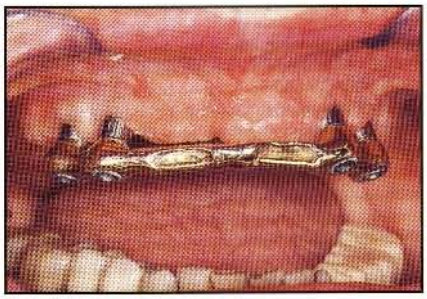

Fig 4b *Splinted anterior implant-supported bar.*

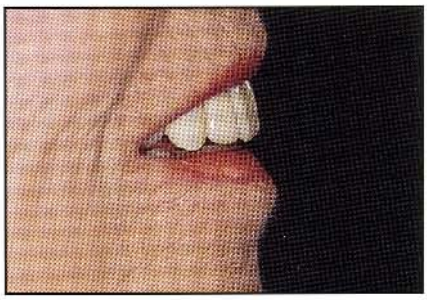

Fig 4c *Profile view of normal tooth and lip contours relative to the incisal plane that were developed with the prosthetic overdenture flange (Fig 3); a fixed bridge design "would cause excessively long buccal flared teeth with large interproximal spaces or visible abutments entering the mucosa."*[14]



Fig 5a *Note radiographic evidence of severe periodontitis of all remaining maxillary teeth.*

Fig 5b *Severely compromised maxillary teeth with posterior bite collapse and anterior diastema formation.*



Fig 5c *Severe periodontitis of all remaining maxillary teeth.*

Fig 6a *Ceramogold implant-supported anterior fixed splint with female ASC-52 attachment. Endosseous implant abutments are distributed throughout the premaxilla and placed as far distal as the maxillary sinuses would allow.*

Fig 6b *ASC-52 male attachment.*

Fig 6c *Anterior ceramogold implant-supported restoration with distal extension precision partial denture posteriorly. Note the indirect retention more anteriorly (Fig 3).*

Fig 7a (left) *Natural emergence profiles of implant-supported ceramogold crowns.*

Fig 7b (right) *Fixed anterior implant-supported (cement-retained) ceramogold restoration with distal extension precision partial denture posteriorly.*

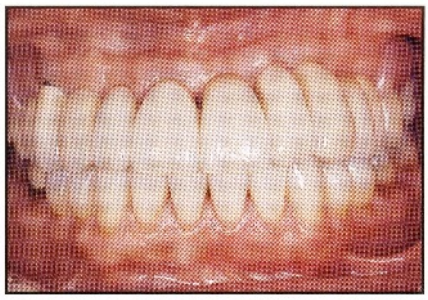

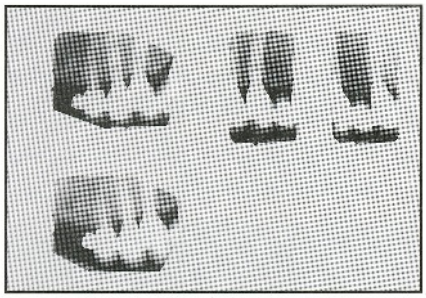

Fig 8a *Periapical radiographs of implant and tooth abutments anterior to the maxillary sinuses. Endosseous implant placement by Dr Alan Singer, Washington, DC.*

Fig 8b *Fixed anterior ceramogold splinted implant-supported restoration. Favorable incisal plane and lifelike individuality of anterior ceramogold crownwork.*

Fig 8c *Implant and tooth abutments anterior to the maxillary sinuses.*

of the final laboratory work. All copings were waxed and cast, and the female attachments were waxed to the distal-most anterior abutments bilaterally to be cast with their respective copings. The implant and tooth abutment copings were then seated and checked for individual fit. They were attached together with GC pattern resin, and the framework was soldered.

The framework was tried in for collective fit and then with the partial denture base. The males were set into the female attachments and luted to the posterior partial denture base with GC pattern resin, while the base was gently compressed against the palatal tissues. The male connector was a spring-loaded ball connector with adjustable retention (Fig 6). The fact that the connector allows movement in all three planes classifies it as a stress-relieving attachment. This may be one of the few situations in which stress relief is valuable, preventing any overtaxing of the anterior implant group. The attachments were soldered to the metal base, the ceramic was baked to the anterior fixed framework, and all prosthetic components were collectively tried in. The ASC-52[15] ball attachment is a small universal joint connector that allows both vertical and rotational movements (Fig 6).

After checking and adjusting the occlusion of the anterior fixed restoration, acrylic bite blocks registered the final occlusal relations for the partial denture base bilaterally. Upon completion, the anterior ceramogold bridge/splint was luted into place with dental luting cements and/or appropriate set screws, and the precision partial denture was inserted and evaluated for fit and stability (Figs 7 and 8). The patient was instructed to take note of any mucosal irritations and have them attended to as soon as they presented.

The patient was maintained on a regular 3-month hygiene recall. It

is of interest to note that in the future, sinus augmentation and implant placement may still be performed posteriorly and the removable prosthesis may be exchanged for implant-supported crownwork.

For the patient demonstrating minimal anterior ridge resorption with minimal alveolar bone height posteriorly, an anterior fixed-splinted implant-supported restoration with a precision partial denture posteriorly is offered as an alternative restoration to the removable implant-supported bar-and-clip or ball-retained overdenture or spark-erosion implant prosthesis.

Acknowledgments

Thank you to Sylvie Rupple-Bozilov for her technical expertise in the preparation of this manuscript. A special thank you to Drs Morton Amsterdam, Arnold Weisgold, Edwin Rosenberg, and Leonard Abrams for their educational support and guidance.

References

1. Amsterdam M, Ingber J. The Distal Extension Case—Tooth-Tissue Borne Removable Appliance, Vol 1 (No. 9). Univ of Pennsylvania, Continuing Dental Education, 1978.
2. Amsterdam M. Periodontal prosthesis—Twenty-five years in retrospect. Alpha Omegan 1974;67(3):8–52.
3. Amsterdam M, Abrams L. Periodontal prosthesis. In: Goldman HM, Cohen DW (eds). Periodontal Therapy, ed 5. St Louis: Mosby, 1973.
4. Nyman S, Lindhe J, Lundgren D. The role of occlusion for the stability of fixed bridges in patients with reduced periodontal tissue support. J Clin Periodontol 1975;2(2):53–66.
5. Hindels GW. Load distribution in extension saddle partial dentures. J Prosthet Dent 1952;2:92–100.
6. Preiskel HW. Precision Attachments in Dentistry—An Introductory Manual. St Louis: Mosby, 1996:60–61.
7. Naert I, Quirynen M, van Steenberghe D, Darius P. A six-year prosthodontic study of 509 consecutively inserted implants for the treatment of partial edentulism. J Prosthet Dent 1992;67:236–245.
8. Wallace SS, Froum SJ, Tarnow DP. Histologic evaluation of the sinus elevation procedure. A clinical report. Int J Periodontics Restorative Dent 1996;16: 47–51.
9. Froum SJ, Tarnow DP, Wallace SS, Rohrer MD, Cho SC. Sinus floor elevation using anorganic bovine bone matrix (Osteograf/N) with and without autogenous bone: A clinical, histologic, radiographic, and histomorphometric analysis—Part 2 of an ongoing prospective study. Int J Periodontics Restorative Dent 1998;18:528–543.
10. Keller EE, Tolman DE, Eckert SE. Maxillary antral-nasal inlay autogenous bone graft reconstruction of compromised maxilla: A 12-year retrospective study. Int J Oral Maxillofac Implants 1999;14:707–721.
11. Keller EE, Tolman DE, Eckert S. Surgical-prosthetic reconstruction of advanced maxillary bone compromise with autogenous onlay block bone grafts and osseointegrated endosseous implants: A 12-year study of 32 consecutive patients. Int J Oral Maxillofac Implants 1999;14: 197–209.
12. Sadowsky SJ. The implant-supported prosthesis for the edentulous arch: Design considerations. J Prosthet Dent 1997;78:28–33.
13. Desjardins RP. Prosthesis design for osseointegrated implants in the edentulous maxilla. Int J Oral Maxillofac Implants 1992;7:311–320.
14. Zitman N, Marinello G. Treatment plan for restoring the edentulous maxilla with implant-supported restorations: Removable overdenture versus fixed partial denture design. J Prosthet Dent 1999;82: 188–196.
15. Staubli P. Attachments and Implants, Reference Manual, ed 6. Attachments International, 1996:20.
16. Ganz SD. Combination natural teeth and implant-borne removable partial denture: A clinical report. J Prosthet Dent 1991;66: 1–5.
17. Jang Y, Emtiaz S, Tarnow DP. Single implant-supported crown used as an abutment for a removable cast partial denture: A case report. Implant Dent 1998;7:199–204.
18. Pellecchia M, Pellecchia R, Emtiaz S. Distal extension mandibular removable partial denture connected to anterior fixed implant-supported prosthesis: A clinical report. J Prosthet Dent 2000;83:607–612.